

See discussions, stats, and author profiles for this publication at: <https://www.researchgate.net/publication/259502381>

# Effectiveness of Hyperbaric Oxygen and Ozone Applications in Tissue Healing at Generated Soft Tissue Trauma Model of Rats: An Experimental Study

**Article** in *Ulusal travma ve acil cerrahi dergisi = Turkish journal of trauma & emergency surgery: TJTES* · May 2014

DOI: 10.5505/tjtes.2014.09465

CITATIONS

14

READS

260

12 authors, including:



**Ali Osman Yıldırım**

Gulhane Military Medical Academy

53 PUBLICATIONS 228 CITATIONS

[SEE PROFILE](#)



**Mehmet Eryilmaz**

Sağlık Bilimleri Üniversitesi

82 PUBLICATIONS 267 CITATIONS

[SEE PROFILE](#)



**Murat Eroglu**

GATA Haydarpaşa Training Hospital

58 PUBLICATIONS 230 CITATIONS

[SEE PROFILE](#)



**Murat Durusu**

Kudret International Hospital, Ankara, Turkey

57 PUBLICATIONS 247 CITATIONS

[SEE PROFILE](#)

Some of the authors of this publication are also working on these related projects:



Use of hyperbaric oxygen therapy in different pathophysiological conditions [View project](#)



Seeking for therapeutic potentials of mustard toxicity [View project](#)

# Effectiveness of hyperbaric oxygen and ozone applications in tissue healing at generated soft tissue trauma model of rats: an experimental study

Ali Osman Yıldırım, M.D.,<sup>1</sup> Mehmet Eryılmaz, M.D.,<sup>2</sup> Ümit Kaldırım, M.D.,<sup>2</sup> Yusuf Emrah Eyi, M.D.,<sup>3</sup> Salim Kemal Tuncer, M.D.,<sup>2</sup> Murat Eroğlu, M.D.,<sup>1</sup> Murat Durusu, M.D.,<sup>2</sup> Turgut Topal, M.D.,<sup>4</sup> Bülent Kurt, M.D.,<sup>5</sup> Serkan Dilmen, M.D.,<sup>6</sup> Serkan Bilgiç, M.D.,<sup>7</sup> Muhittin Serdar, M.D.<sup>8</sup>

<sup>1</sup>Department of Emergency Medicine, Gmma, Haydarpasa Military Hosital, Istanbul;

<sup>2</sup>Department of Emergency Medicine, Gmma School of Medicine, Ankara;

<sup>3</sup>Department of Emergency Medicine, Hakkari Military Hospital, Hakkari;

<sup>4</sup>Department of Physiology, Gmma School of Medicine, Ankara;

<sup>5</sup>Department of Pathology, Gmma School of Medicine, Ankara;

<sup>6</sup>Department of Emergency Medicine, Elazig Military Hospital, Elazig;

<sup>7</sup>Department of Orthopedics, Gmma, Haydarpasa Military Hosital, Istanbul;

<sup>8</sup>Department of Biochemistry, Gmma School of Medicine, Ankara

## ABSTRACT

Soft tissue trauma is a kind of acute traumatic ischemia. We thought that edema, inflammation and ischemia caused by the trauma could be affected positively by hiperbaric oxygen(HBO) and ozone therapy. Soft tissue trauma was generated on the total of 63 adult male Sprague-Dawley rats. Subsequently rats were divided into 2 groups. First group was treated with ozone and the other one was treated with HBO. Tissue and blood samples were taken at the end of the procedures. Tissue LPO, SOD, GSH-Px, INOS, HO-I and HIF I levels were detected. Hematoxylin-eosin staining was used to determine the inflammation and edema histopathologically. We also detected the HIF I activity which decreases when the oxygen concentration increases, the HO-I activity which has anti-inflammatory effects and INOS activity which releases in any kind of acute cases. Eventually we have determined statistically significant reduction in the levels of INOS and LPO in both HBO and ozone groups. Significant decrease of inflammation were detected on both ozone and HBO groups compared with control groups and significant decrease in edema was detected in all three groups as compatible with results above. We think that HBO and ozonotherapy have beneficial effects on biochemical and histopathological findings. Related clinical trials would be helpful to reveal the effects.

**Key words:** Experimental; hiperbaric oxygen; ozone; soft tissue trauma.

## INTRODUCTION

Soft Tissue Traumas (STT) is one of the situations commonly encountered in emergency departments. STT defines the le-

sions of the musculoskeletal system tissues other than bone. The lesions of these tissues are the most commonly seen group of all sports injuries.<sup>[1]</sup>

Crush injuries or acute soft tissue injuries are an important health problem that could threaten the viability and function of the tissues.<sup>[2]</sup> The Crush injuries maybe defined as a kind of acute traumatic ischemia too. The cause of ischemia is cutting or crushing of large vessels, stasis or reduction in microcirculation secondary to occlusion. As a result, adequate tissue perfusion to provide the metabolic needs of the tissue is not achieved. In the early phase of crush, tissue oxygen requirement is increased 20-fold or more to provide good wound healing and control of infection. These metabolic needs can not be provided without increased blood flow. When ischemia increases the tissues can not maintain the intracellular

Address for correspondence: Ali Osman Yıldırım, M.D.  
Gülhane Askeri Tıp Akademisi Haydarpasa Hastanesi,  
Acil Tıp Anabilim Dalı, İstanbul, Turkey  
Tel: +90 533 - 369 09 01 E-mail: draliosmanyildirim@gmail.com

Quçik Response Code



Ulus Travma Acil Cerr Derg  
2014;20(1)  
doi: 10.5505/tjtes.2014.09465

Copyright 2014  
TJTES

fluid content, because oxygen is required for active transport. Therefore, this process is accompanied by edema and inflammation.<sup>[3]</sup>

Hyperbaric oxygen (HBO) therapy is based on ventilating the patient 100% oxygen over atmospheric pressure in a pressure resistant room. HBO improves perfusion by increasing the level of free oxygen in the blood. In this way, cell viability, energy production, and the production of collagen which is important in wound healing is maintained.<sup>[4]</sup>

Ozone is a molecule consisting of three oxygen atoms. Ozone therapy is performing of a certain amount of oxygen / ozone mixture into the body cavities or circulatory system. Ozone reduces the amounts of antioxidants in plasma by reacting them. The hydrogen peroxide which occurs at this time is responsible for the biological and therapeutic effects of ozone. Decreasing in antioxidant level and the stimulating effect of hydrogen peroxide emerges a shock effect on body in the ozone contacting process. As a result of this effect a variety of defense systems including primarily the antioxidant enzyme expression are stimulated. Thus, resistance to the oxidative processes increases. One of the first effects of hydrogen peroxide which is thought to be one of the molecules that responsible for the therapeutic activity of ozone is slipping the hemoglobin-oxygen to the right and releasing of oxygen to the tissues easily by increasing 2,3-diphosphoglycerate levels of red blood.<sup>[5]</sup> The situation emerged during the ozone therapy may be interpreted as increasing of tissue partial oxygen pressure obtained with the help of pressure is providing biochemically with ozone.

Patients with soft-tissue trauma admit the doctor with complaints such as swelling, limitation of movement and pain. There are various approaches to the treatment of these patients who are diagnosed excluding of bone and other pathologies with physical examination and imaging. Supporting of foot and ankle with materials such as plaster, splints and bandages, elevation, cold application, topical non-steroidal inflammation-suppressing drugs, vascular dilators, blood clot dissolving drugs and antioxidants are the commonly used treatment methods of soft tissue edema, ischemia and inflammation. To demonstrate the effectiveness of hyperbaric oxygen and ozone therapy on STT may provide new perspectives on this issue. For this purpose in this study the effectiveness of hyperbaric oxygen and ozone in soft tissue trauma is investigated.

## MATERIALS AND METHODS

The study was approved by the decision of GATA Command Ethics Committee for Animal Experiments on third of March 2011 and with the decision number 2011/11. Animals were supplied by GATA - Research and Development Center - Department of Experimental Animals and were kept at the same laboratory conditions during the study. The animals were fed with commercial rat chow and tap water.

In this study, total 63 adult male, in 230±20 g weight Sprague-Dawley rats were used. The rats were divided into a total of 3 groups using 'simple random sampling' method. Initially the experimental STT was performed each of them, and then the ozone procedure was performed one group (Ozone+STT group) and the HBO procedure was performed one (HBO+STT group) of them (Table 1). There were three groups each contains 21 rats. At 1st, 3rd and 7th days, the samples were taken from seven rats randomly at each groups and compared accordance of time.

## Experimental Acute Soft Tissue Injury Model

The animals were anesthetized with a combination of Intraperitoneally (IP) ketamine (20-40 mg / kg) and xylazine (4 to 8 mg / kg). The subjects were fixed in prone position, the rear leg was shaved and the trauma application location was marked with tissue pen (Figure 1a). The soft tissue trauma was created using a 0.5 kg weight which is released for free fall movement from 45 cm height, in a 3 cm diameter plastic tube, with a 90 degree angle on left rear leg of rat (Figure 1b).

## Hyperbaric Oxygen Therapy

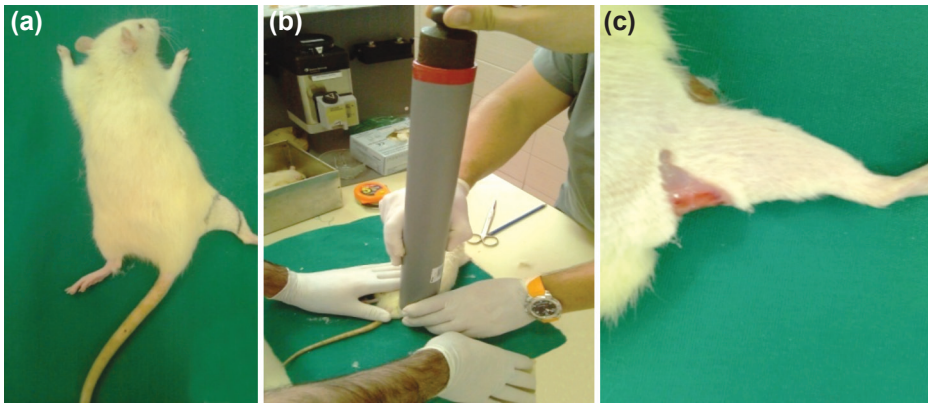
For the application of hyperbaric oxygen, a cylindrical hyperbaric chamber which was specially designed and manufactured with a diameter of 40 cm, length 60 cm in T.S.K. 800 Main Warehouse and Factory Command (Etimesgut / Ankara), had a chromium, nickel and steel mixture body and had been tested resistance to 10 ATA pressure was used. 1,5-2 lt / min flow rate of oxygen input into the chamber was provided by using tubes which contain pure oxygen under high pressure and obtained from GATA - Biomedical Clinical Engineering Centre - Medical Gases department. After the animals of HBO+STT group are placed in chamber, HBO therapy was applied for 2 hours/per day under 2, 5 ATA application pressure and with fixed oxygen amount. At the end of the session, it returned to environment pressure with a slower rate. This procedure was repeated during 3 and 7 days. After HBO therapy, subgroups of animals (1, 3 and 7 days) were sacrificed.

## Ozone Application

Intraperitoneally (IP), the ozone / oxygen mixture, 0,7 g / kg was administered to the rats in ozone group at 1,3 and 7 days. Ozone is created by an ozone generator (OZONOSAN photonic 1014, Hans GmbH Nordring & Iffezheim, Germany)

**Table 1.** Working groups

Groups	Days		
	1st day	3th day	7th day
Ozone + STT	7 RAT	7 RAT	7 RAT
HBO + STT	7 RAT	7 RAT	7 RAT
STT (Control)	7 RAT	7 RAT	7 RAT



**Figure 1.** (a, b) Procedure for soft tissue trauma, (c) taking tissue samples.

in which was placed a spectrometer that allows you to control real-time gas flow rate and ozone concentration. Ozone flow rate was kept constant at 60 mg/ml concentration, 97% oxygen + 3% ozone gas mixture and 3 L/min.

### Taking Samples

After creating an experimental model of soft-tissue trauma, on 1st, 3th and 7th days, tissue and blood samples were taken from each subgroup including 7 rats. After anesthesia, required blood samples were taken from inferior vena cava. Traumatic tissue samples were cutten out and placed in 10% formalin for histopathological analysis. A portion of traumatic tissue was frozen with liquid nitrogen and stored at -80 °C deep freeze for subsequent biochemical assessments (Figure 1c).

### Biochemical Analysis

Routine biochemistry levels to follow-up the general condition of the animal, tissue Lipide Peroxidase (LPO) levels to detect the level of tissue oxidative stres and the tissue su-

peroxit dismutase (SOD) and glutation peroxidazse (GSH-Px) enzyme levels to detect antioxidant system functionality were measured. In addition, to determinate the recovery of hypoxic tissues, Hypoxy Induced Factor (HIF-1) and Heme oxygenase (HO-1) levels and to determinate the wound healing, inducible Nytric oxide synthase (iNOS) levels were measured.

### Histopathological evaluation

After trauma and administration of 7 days hyperbaric oxygen and ozone treatment; edema, inflammation and necrosis in tissue were evaluated and scored by an experienced pathologist. Injured skeletal muscle and adipose tissue extracted from rare thigh. Tissues were fixed in 4% buffered formaldehyde. Tissues were sampled completely, paraffin blocks were obtained and 5 micron thickness slides were prepared. Slides were stained with haematoxylin-eosin. Evaluation and scoring were made by light microscope (Nikon, E600, and Tokyo, Japan)

Histological scoring was made as follows:

**Table 2.** Comparison of tissue enzyme levels of all group according to the days

	LPO nmol/g Mean.±SD	SOD U/mg Mean.±SD	HO-1α nmol/g Mean.±SD	HIF-1 pg/mg Mean.±SD	iNOS IU/mg Mean.±SD	GSH-PX nmol/min/mg Mean.±SD
1st day	69.54±14.5	7.55±3.2	1169.8±251.2	73.34±22.15	38.70±16.6	10.73±2.31
3th day	53.60±12.6	6.15±2.48	1091.71±243.8	37.92±15.53	31.73±9.15	9.20±3.05
7th day	43.98±20.54	5.37±2.29	838.85±348.44	22.74±8.87	24.42±6.35	9.80±3.50
P	0.028	0.337	0.104	<0.001	0.097	0.639
1st day	52.97±16.13	23.44±9.77	1191±322.90	50.35±17.35	70.39±23.31	27.50±9.94
3th day	15.29±5.11	18.65±7.40	1105.71±262.7	40.61±13.92	46.73±17.27	6.86±3.05
7th day	17.46±8.92	11.7±1.91	866.71±290.01	28.52±10.51	27.4±9.91	7.11±2.87
P	<0.001	0.023	0.128	0.033	0.001	<0.001
1st day	62.54±14.74	18.36±6.53	1067.57±291.92	56.48±32.01	79.25±23.96	12.25±3.19
3th day	33.61±9.84	10.92±4.36	715.50±178.61	35.15±12.09	43.08±23.21	9.49±2.48
7th day	24.29±7.57	4.05±1.87	969.33±356.1	31.58±10.14	16.38±3.9	4.92±2.25
P	<0.001	<0.001	0.109	0.105	<0.001	0.001



1- Edema: absent: 0, mild: 1+, moderate: 2+, intense: 3+  
 2- Inflammation: absent: 0, mild: 1+, moderate: 2+, intense: 3+  
 3- Necrosis: absent: 0, mild: 1+ (e few muscle fibres), moderate: 2+ (between score 1 and 3), intense: 3+ (many muscle fibres)  
 As it is seen in table, minimum score 0 and maximum score was 9.

## Statistical Analysis

The numbers (%) for defining the discrete data points, and median (25% - 75%) values for defining continuous datas were used. The Kruskal-Wallis test is used in all groups comparisons and then Mann-Whitney U test was used to compare the groups in pairs which had significant results. Chi-square or Fisher's exact test was used in comparison of the discrete datas between the two groups. The simultaneous changes of continuous variables were assessed by Spearman relevant coefficient.  $p < 0.05$  values were considered significant.

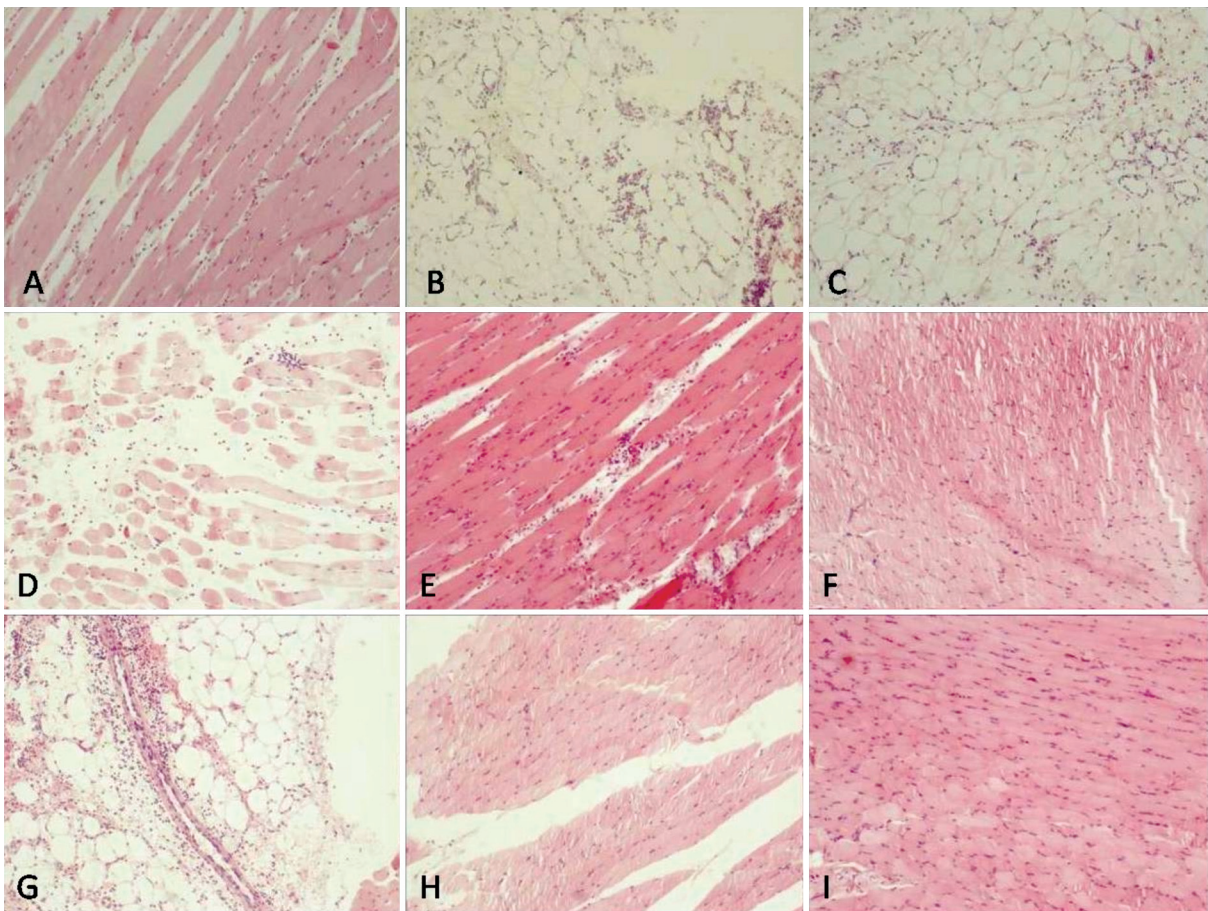
## RESULTS

### Biochemical Results

In tissue samples analysis a significant decrease in LPO levels

was observed in HBO and ozone groups comparing to control group by 1,3 and 7th day. There was a significant decrease in SOD, GSH-PX and INOS levels only in the treatment groups (Table 2). The values of all of the parameters in serum samples were measured significantly lower on 7th day according to 1st day except on SOD/GSH-PX in HBO group and on SOD/INOS in ozone group (Table 3). The values of LPO, HIF-1, HO-1 $\alpha$ , GSH-PX, SOD and INOS from tissue samples are presented in Table 2 and the values of LPO, HIF-1, HO-1 $\alpha$ , GSH-PX, SOD and INOS from serum samples are presented in Table 3.

Binary comparisons of the parameters between the Control and HBO groups for tissue at 1st day; SOD, iNOS and GSH-PX levels of HBO groups were significantly higher than control group ( $p < 0.001$ ,  $p = 0.001$  and  $p < 0.001$ , respectively). LPO and HIF-1 levels of HBO group were significantly lower than Control group ( $p = 0.023$  and  $p = 0.017$ , respectively). At 3rd and 7th days, LPO levels of HBO were significantly lower than Control group ( $p < 0.001$  and  $p < 0.001$ , respectively) and SOD levels of HBO group were significantly higher than Control group  $p < 0.001$  and  $p = 0.027$ , respectively). HIF-1, iNOS and GSH-PX levels of HBO and Control groups were not



**Figure 2.** Intense edema and inflammation between muscle fibres and e few necrotic muscle fibre (control group, first day) (a). Moderate edema and inflammation in adipose tissue (HBO group, first day) (b). Moderate edema and inflammation in adipose tissue (Ozone group, first day) (c). intense edema and inflammation (control, 3th day) (d). Moderate edema and inflammation in muscle tissue (HBO, 3th Day) (e). Mild infammation in muscle tissue (f). Mild infammation in muscle tissue (Ozone 3th day) (g). Moderate edema and inflammation in adipose tissue (Control, 7th day) (h). Mild inflammation and edema (HBO, 7th. day) (I).

**Table 3.** Comparison of serum enzyme level of control, HBO and ozone groups according to the 1th and 7 th days

	<b>LPO</b> nmol/L Mean.±SD	<b>SOD</b> U/ml Mean.±SD	<b>HO-Iα</b> ng/ml Mean.±SD	<b>HIF-I</b> pg/ml Mean.±SD	<b>iNOS</b> IU/ml Mean.±SD	<b>GSH-PX</b> nmol/min/ml Mean.±SD
<b>Control</b>						
1st day	4.99±1.03	0.96±0.40	280.10±69.81	15.73±2.90	3.80±0.91	1.67±0.34
7th day	2.85±0.91	0.24±0.16	201.33±20.64	13.15±3.64	3.32±0.94	0.80±0.28
P	0.001	0.001	0.014	0.168	0.354	<0.001
<b>HBO</b>						
1st day	3.07±0.72	1.90±0.38	410.94±97.27	25.14±9.19	4.31±0.62	1.56±0.49
7th day	1.37±0.40	2.66±1.06	268.86±80.24	22.28±3.25	4.02±0.92	1.81±0.28
P	<0.001	0.102	0.011	0.453	0.499	0.270
<b>OZONE</b>						
1st day	1.66±0.47	1.74±0.63	439.15±58.12	34.65±7.45	2.46±0.68	1.52±0.30
7th day	1.35±0.25	2.70±0.58	143.45±41.94	7.89±3.67	4.79±1.57	1.20±0.71
P	0.175	0.017	<0.001	<0.001	0.004	0.307

statistically significant at 3rd and 7th days. There was no statistically significant in HO-Iα levels at 1st, 3rd and 7th days between the control and HBO groups.

Binary comparisons of the parameters between the Control and Ozone groups for tissue; SOD and iNOS levels of Ozone group were significantly higher than Control group at 1st

day (p<0.001 and p<0.001, respectively). LPO and HO-Iα levels of Ozone group were significantly lower than Control group at 3rd day (p=0.009 and p=0.023 respectively). LPO and GSH-PX levels of Ozone group were significantly lower than control group at 7th day (p=0.010 and p=0.048 respectively). Other parameters were not statistically significant between Ozone and Control groups.

**Table 4.** Comparison of Edema, necrosis and inflammation in the Control, HBO and Ozone groups according to days 1,3 and 7

	Control					HBO					Ozone			
	Days			p		Days			p		Days			p
	1st	3rd	7th			1st	3rd	7th			1st	3rd	7th	
Edema														
0	0	0	0	<0.001	0	0	0	<0.001	0	7	7	<0.001		
(+)	0	0	0		0	0	7		0	0	0			
(++)	0	0	7		7	7	0		7	0	0			
(+++)	7	7	0		0	0	0		0	0	0			
Necrosis														
0	0	7	7	<0.001	7	7	7	(*)	7	7	7	(*)		
(+)	7	0	0		0	0	0		0	0	0			
(++)	0	0	0		0	0	0		0	0	0			
(+++)	0	0	0		0	0	0		0	0	0			
Inflammation														
0	0	0	0	(*)	0	0	0	<0.001	0	0	7	<0.001		
(+)	0	0	0		0	0	7		0	7	0			
(++)	7	7	7		0	7	0		7	0	0			
(+++)	0	0	0		7	0	0		0	0	0			

(\*) Chi-square test could not be applied.

## Histopathological Findings

In all groups, total score was less in 3rd and 7th days than in 1st day. First day score of ozone group was lower than first day score of control and hyperbaric oxygen groups. Seventh day score of ozone group was lower than hyperbaric oxygen group.

In the control group, edema was intense in 1st and 3rd days, but, it was moderate in 7th day. The difference between 1st or 3rd vs. 7th was statistically significant ( $p < 0.001$ ). Inflammation was moderate on all days; therefore Chi-square test could not be applied. When necrosis was mild on 1th day, it was absent on 3rd and 7th day in control group. This is also statistically significant ( $p < 0.001$ ), (Table 4).

In the HBO group, edema was moderate on 1st and 3rd days, but on 7th day it was mild. Inflammation was intense, moderate and mild on 1th, 3rd and 7th days, respectively. This decrement in the HBO group was statistically significant. But, necrosis has not seen in HBO group for all days (Table 4).

In ozone group, first day, edema was moderate but 3rd and 7th days, edema was absent. Inflammation was moderate, mild and absent on 1th, 3rd and 7th days, respectively. This decrement in the ozone group was statistically significant ( $p < 0.001$ ). Necrosis has not seen in this group (Table 4.)

Examples of histopathological images of the control and treatment groups are presented in Figure 3.

## DISCUSSION

In the review of the literature about models of soft-tissue trauma, there are methods created by chemicals (such as zymosan), ultraviolet radiation and mechanically (or physically). The components of the immune system are also activated when trying to create an inflammation model using antigenic substances such as Freud adjuvant, carrageenan or zymosan. However, soft-tissue injuries that occur in reality are usually sterile. There is also sterilized injury models created by U.V too.<sup>[6]</sup> This injury model was developed on the model of traumatic brain injury studies in rats.<sup>[7,8]</sup>

There are various clinical studies in the literature about HBO effectiveness in STT treatment. The common belief in these studies is that the HBO is not effective in soft tissue trauma treatment. However, review of the Cochrane Collaboration, published in 2009 expressed limitations of the studies and necessity of more comprehensive further studies. Although efficacy of ozone in the inflammatory process is known, we couldn't reach any study in the literature on the use of soft tissue trauma except the lumbar disc herniation and orthopedic disorders including arthritis and rheumatic diseases.<sup>[14-19]</sup> Brooke et al had performed HBO therapy to 21 collegian volunteers who had exercise induced muscle injury in their study and they concluded that HBO therapy is not effective

treatment of muscle injury. It's thought that because it's not possible to standardize the soft tissue trauma severity this result is emerged. One of the other factors that HBO treatment not to be successful may be the structures such as muscle ligaments, tendons and fascia are also affected, and these structures have much less response to oxygen.<sup>[14]</sup>

Soolsma could'n find any evidence of HBO treatment's benefit on delayed muscle pain treatment process in his grade 2 medial collateral ligament injuries study, in 1996.<sup>[20]</sup> In four studies there were results that HBO significantly decreases pain of patients at the end of 48 hours but there weren't any evidence of improvement in muscle tension and decrease in edema. There was no difference between signs of edema and muscle tension in both groups. There was no significant difference in clinical outcomes after 24 hours delayed HBO treatment in study of Harrison and Staples too.<sup>[11,14,21]</sup> The reason of these results those don't appear compatible with ours is thought to be due to use of ligament injury as a model and limited response of ligaments to the oxygen.

Ozone therapy has shown positive effects on wound healing, age-related macular degeneration, ischemic and infectious diseases in the case - analysis studies. In addition, it's effectively applied to a variety of infectious diseases ranging from simple dental or mouth infections to hepatitis.<sup>[22,23]</sup>

It's surprising the therapeutic effect of ozone especially at the pathophysiological situations due to intense inflammatory process in which the immune system is forefront. Martinez-Sanchez and his colleagues applied HBO treatment to the patients who had diabetic foot and they reported that wound healing was accelerated, length of hospital stay was shortened, control of blood sugar levels was better and antioxidant enzyme levels were increased in HBO treatment group according to antibiotic treatment group.<sup>[16]</sup> And also it's reported that injection of oxygen / ozone mixture into the disk is useful on lumbar disc herniations.<sup>[17]</sup> The studies shown that ozone applications increase the secretion of PDGF, TGF- $\beta$ 1, and cytokines such as IL-8 from platelets. Kim et al also showed the same results with their wound healing study. In this study, topically applied ozone increased PDGF, TGF and VEGF expression and accelerated wound healing in scar tissue.<sup>[18]</sup> Koca et al showed that inflammatory cytokines and oxidative stress decreased in ozone group at least HBO group recently.<sup>[19]</sup>

There are important studies in the literature about how the HBO application affects the antioxidant enzymes in various tissues in the organism. In one of them, Harabin and his colleagues reported increase in SOD activity in the lung and decrease in GPX activity in brain and lung tissues in HBO applied rats and guinea pigs.<sup>[24]</sup> There are also other researches too which report that HBO may lead to an increase in SOD activity. These results seem compatible with our work results.

Although increasing in antioxidant enzyme activities indicate an increase in free radical production, this increasing has



importance especially when these enzymes exceed the capacity. The lipid peroxidation which is one of the the most important harmful effects of free radicals must be evaluated to assess effect of increased free radical level. The best indicator of this is lipid peroxidase. In our study, decrease in lipid peroxidase levels was statistically significant in HBO group according to control group on 1st, 3th and 7th days, decrease in lipid peroxidase levels was insignificant on 1st day and was statistically significant on 3th and 7th days. These values show that decrease in LPO level was less in control group than ozone and HBO groups. This situation may show that there is an intense oxidative stress that exceeds the capacity antioxidant enzymes in trauma created.

The organisms needing Oxygen for life must have physiological adaptation to hypoxia. In mammals including humans, vasodilation, angiogenesis, increase in glucose transport, increase in glukoliz and apoptosis is activated. In the treatment of tumor, antianjiyogenezis reduces the tumor blood flow resulting the tumor cells to become resistant to chronic hypoxia. It's found that the signaling pathway that stimulated by hypoxia improves the acquired tolerance to chronic hypoxia. HIF1  $\alpha$  controls this by influencing apoptosis and regulating genes and VEGF.<sup>[26,27]</sup> Reduction of oxygen in a region increase the production of gene regulatory protein "hypoxia-inducible factor 1 - (HIF1)". This protein increases VEGF production particularly affecting VEGF gene promoter. The VEGF secreted by surrounding tissue increases vasculature by activating endothelial cells in this region. When the formation of new blood vessels occurs and the oxygen concentration increases, HIF1 activity and VEGF production decreases.<sup>[28]</sup> In our study, there is a statistically significant decrease in the control and HBO groups between days. In ozone group, it was statistically insignificant. Decrease in the level of HIF-1 between the control and HBO groups was statistically significant on day 1 and was statistically insignificant on day 3 and day 7. Based on these findings it's known that HBO therapy has more active role than the ozone treatment in tissue oxygenation especially in the early days of the trauma.

It's reported that With application of ozone hemoxygenase-I (HO-I) enzyme is also stimulated. The reason of the increase of this enzyme may be due to red blood cell hemolysis or ROT. HO-I is a microsomal enzyme which involved in the demolition way of hem ring and the production is stimulated by increase in oxidative stress, inflammatory cytokines and nitric oxide (NO). This enzyme smashes hem molecule in biliverdin and carbon monoxide (CO). In several studies performed in recent years showed that HO-I enzyme had antioxidant, anti-inflammatory and antiapoptotic.<sup>[29-31]</sup> However, in a study it's demonstrated that induction of hemoksijenaz is one of the protective mechanisms against oxidative stress in the pathogenesis of pulmonary disease. HO-I, the Inducible form of the HO catalyzes hem to bilirubin and this causes free iron and CO production.<sup>[32]</sup> In our study, change in HO-I activity between groups were not significant according to days. The protection of HO-I levels is considered to be significant in our study in which, the enzyme levels was decreased generally.

INOS that released in any acute event (trauma, stress, acute

inflammation, etc.) may have either protective or a detrimental effect on tissue. NO is important in wound healing. NO synthesis by macrophages continues for a long time in vitro. NO produced by structural NOS is necessary to maintain the normal physiological events. High NO concentrations produced by inducible NOS increases the damage.<sup>[33]</sup> In short, NO molecule may show either protective or damaging effects in acute inflammatory events. Immediately after the trauma, the level of iNOS increases In burning wounds too. Koca et al. created skeletal muscle ischemia-reperfusion injury in rats and reported that HBO treatment decreased MDA and NOS levels, increased significantly GSH-Px enzyme activity.<sup>[19]</sup> These findings seem to be compatible with our study. On histopathologic examination of tissues exposed to trauma, the inflammation was more significantly decreased in treatment groups than control group. Histopathological findings support the biochemical findings.

As a result of the study findings and the literature review we find that there are laboratory results marking that ozone and HBO reduces oxidative stress, improves tissue healing and increases tissue partial oxygen pressure. These results are supported by significant reduction in inflammation and edema on histopathological examination in treatment groups. As a result, the ozone and HBO treatments in soft tissue trauma are considered to be of benefit in accordance with biochemical and histopathological findings in our study. However, we couldn't reach any clear result that shows HBO and ozone has superiority to each other. Further studies on this subject, which is a popular topic in the treatment of soft tissue injuries, can provide new insights.

Conflict of interest: None declared.

## REFERENCES

1. Yucesir I, Bayraktar B. Soft Tissue Injuries and Principles of Healing. Türkiye Klinikleri J Orthop & Traumatol-Special Topics 2010;3(1):24-8.
2. Bywaters EG, Beall D. Crush injuries with impairment of renal function. 1941. J Am Soc Nephrol. 1998;9(2):322-32.
3. Mabvuure NT, Malahias M, Hindocha S, Khan W, Juma A. Acute compartment syndrome of the limbs: current concepts and management. Open Orthop J. 2012;6:535-43.
4. Feldmeier JJ. Hyperbaric oxygen 2003: Indications and results: The Hyperbaric Oxygen Therapy Committee Report. Undersea and Hyperbaric Medical Society, Inc., Kensington, MD, 2003.
5. Bocci V. How does ozone act? How and why can we avoid ozone toxicity? In: Bocci V, editor. Ozone; A new medical drug. Dordrecht: Springer; 2005. p. 19-28
6. Davies SL, Siau C, Bennett GJ. Characterization of a model of cutaneous inflammatory pain produced by an ultraviolet irradiation-evoked sterile injury in the rat. J Neurosci Methods. 2005;148(2):161-6.
7. Dixon CE, Clifton GL, Lighthall JW, Yaghmai AA, Hayes RL. A controlled cortical impact model of traumatic brain injury in the rat. J Neurosci Methods. 1991;39(3):253-62.
8. Tavazzi B, Signoretti S, Lazzarino G, Amorini AM, Delfini R, Cimatti M, et al. Cerebral oxidative stress and depression of energy metabolism correlate with severity of diffuse brain injury in rats. Neurosurgery 2005;56(3):582-9.
9. Kranke P, Bennett MH, Martyn-St James M, Schnabel A, Debus SE.



- Hyperbaric oxygen therapy for chronic wounds. *Cochrane Database Syst Rev*. 2012;18(4):CD004123.
10. Babul S, Rhodes EC, Taunton JE, Lepawsky M. Effects of intermittent exposure to hyperbaric oxygen for the treatment of an acute soft tissue injury. *Clin J Sport Med*. 2003;13(3):138-47.
  11. Staples JR, Clement DB, Taunton JE, McKenzie DC. Effects of hyperbaric oxygen on a human model of injury. *Am J Sports Med*. 1999;27(5):600-5.
  12. Germain G, Delaney J, Moore G, Lee P, Lacroix V, Montgomery D. Effect of hyperbaric oxygen therapy on exercise-induced muscle soreness. *Undersea Hyperb Med*. 2003;30(2):135-45.
  13. Bennett MH, Feldmeier J, Hampson N, Smea R, Milross C. Hyperbaric oxygen therapy for late radiation tissue injury. *Cochrane Database of Systematic Reviews* 2009, Issue 3. Art. No: CD005005.
  14. Harrison BC, Robinson D, Davison BJ, Foley B, Seda E, Byrnes WC. Treatment of exercise-induced muscle injury via hyperbaric oxygen therapy. *Med Sci Sports Exerc*. 2001;33(1):36-42.
  15. Bocci V. The case for oxygen-ozone therapy. *Br J Biomed Sci*. 2007;64(1):44-9.
  16. Martínez-Sánchez G, Al-Dalain SM, Menéndez S, Re L, Giuliani A, Candelario-Jalil E, et al. Therapeutic efficacy of ozone in patients with diabetic foot. *Eur J Pharmacol*. 2005;523(1-3):151-61.
  17. Muto M, Ambrosiano G, Guarnieri G, Capobianco E, Piccolo G, Annunziata G, et al. Low back pain and sciatica: treatment with intradiscal-intraforaminal O<sub>2</sub>-O<sub>3</sub> injection. Our experience. *Radiol med*. 2008;113:695-706.
  18. Kim HS, Noh SU, Han YW, Kim KM, Kang H, Kim HO, Park YM. Therapeutic effects of topical application of ozone on acute cutaneous wound healing. *J Korean Med Sci*. 2009;24(3):368-74.
  19. Koca K, Yurttaş Y, Bilgic S, Cayci T, Topal T, Durusu M, et al. Effect of preconditioned hyperbaric oxygen and ozone on ischemia-reperfusion induced tourniquet in skeletal bone of rats. *J Surg Res*. 2010;164(1):83-9.
  20. Soolsma SJ. The effect of intermittent hyperbaric oxygen on short term recovery from grade II medial collateral ligament injuries. Thesis (1996), University of British Columbia, Vancouver.
  21. Mekjavic IB, Exner JA, Tesch PA, Eiken O. Hyperbaric oxygen therapy does not affect recovery from delayed onset muscle soreness. *Med Sci Sports Exerc*. 2000;32(3):558-63.
  22. Stubinger S, Sader R, Filippi A. The use of ozone in dentistry and maxillofacial surgery: a review. *Quintessence Int*. 2006; 37(5):353-9.
  23. Nogales CG, Ferrari PH, Kantorovich EO, Lage-Marques JL. Ozone therapy in medicine and dentistry. *J Contemp Dent Pract*. 2008;9(4):75-84.
  24. Harabin AL, Braisted JC, Flynn ET. Response of antioxidant enzymes to intermittent and continuous hyperbaric oxygen. *J Appl Physiol*. 1990;69:328-35.
  25. Oter S, Korkmaz A, Topal T, Ozcan O, Sadir S, Ozler M, et al. Correlation between hyperbaric oxygen exposure pressures and oxidative parameters in rat lung, brain, and erythrocytes. *Clin Biochem*. 2005;38:706-11.
  26. Carmeliet P, Dor Y, Herbert JM, Fukumura D, Brusselmans K, Dewerchin M, et al. Role of HIF1  $\alpha$  in hypoxia-mediated apoptosis, cell proliferation and tumor angiogenesis. *Nature* 1998;394:485-90.
  27. Communal C, Sumanda M, Tombe P, Narula J, Solaro RJ, Hajjar RJ. Functional consequences of caspase activation in cardiac myocytes. *Proc Natl Acad Sci USA*. 2002;99(9):6252-6.
  28. Alberts B, Johnson A, Lewis J, Raff M, Roberts K, Walter P. *Histology: The lives and deaths of cells in tissues*. In: Alberts B, Johnson A, Lewis J, Raff M, Roberts K, Walter P, editors. *Molecular Biology of the Cell*. 4th ed. New York: Garland Science; 2002, p. 1259-312.
  29. Bocci V, Aldinucci C, Mosci F, Carraro E, Valacchi G. Ozonation of human blood induces a remarkable upregulation of heme oxygenase-1 and heat stress protein-70. *Mediators Inflamm*. 2007; 2007: 1-6.
  30. Fritz HB. Heme oxygenase-1: a therapeutic amplification funnel. *FASEB J*. 2005;19(10):1216-9.
  31. Otterbein LE, Soares MP, Yamashita K, Bach FH. Heme oxygenase-1: unleashing the protective properties of heme. *Trends Immunol*. 2003;24(8):449-55.
  32. Horvath I, Loukides S, Wodehouse T, Kharitonov SA, Cole PJ, Barnes PJ. Increased levels of exhaled carbon monoxide in bronchiectasis: a new marker of oxidative stress. *Thorax* 1998;53:867-70.
  33. Kubes P, McCafferty DM. Nitric oxide and intestinal inflammation. *Am J Med* 2000;109:150-8.

## DENEYSSEL ÇALIŞMA - ÖZET

### Ratlarda oluşturulan yumuşak doku travma modelinde, hiperbarik oksijen ve ozon uygulamalarının doku iyileşmesi üzerine etkinliği, deneysel çalışma

**Dr. Ali Osman Yıldırım,<sup>1</sup> Dr. Mehmet Eryılmaz,<sup>2</sup> Dr. Ümit Kaldırım,<sup>2</sup> Dr. Yusuf Emrah Eyi,<sup>3</sup> Dr. Salim Kemal Tuncer,<sup>2</sup> Dr. Murat Eroğlu,<sup>4</sup> Dr. Murat Durusu,<sup>2</sup> Dr. Turgut Topal,<sup>4</sup> Dr. Bülent Kurt,<sup>5</sup> Dr. Serkan Dilmen,<sup>6</sup> Dr. Serkan Bilgiç,<sup>7</sup> Dr. Muhittin Serdar<sup>8</sup>**

<sup>1</sup>Gata Haydarpaşa Asker Hastanesi, Acil Tıp Anabilim Dalı, İstanbul;

<sup>2</sup>Gata, Askeri Tıp Fakültesi, Acil Tıp Anabilim Dalı, Ankara;

<sup>3</sup>Hakkari Asker Hastanesi, Acil Servis, Hakkari;

<sup>4</sup>Gata, Askeri Tıp Fakültesi, Fizyoloji Anabilim Dalı, Ankara;

<sup>5</sup>Gata, Askeri Tıp Fakültesi, Patoloji Anabilim Dalı, Ankara;

<sup>6</sup>Elazığ Asker Hastanesi, Acil Servis, Elazığ;

<sup>7</sup>Gata Haydarpaşa Asker Hastanesi, Ortopedi Anabilim Dalı, İstanbul;

<sup>8</sup>Gata, Askeri Tıp Fakültesi, Biyokimya Anabilim Dalı, Ankara

Yumuşak doku travmaları bir çeşit akut travmatik iskemidir. Travmayla ortaya çıkan ödem, inflamasyon ve iskemiyi, HBO ve Ozonun olumlu etkileri olacağı düşünüldü. Bu amaçla toplam 63 yetişkin erkek Sprague-Dawley türü sıçanın her birine başlangıçta yumuşak doku travması (YDT) uygulanmış sonrasında bir kısmına ozon, bir kısmına HBO tedavi prosedürü uygulanmıştır. Prosedürler bitiminde doku ve kan örnekleri alınan hayvanlarda, doku oksidatif stres düzeyini tespitite doku LPO düzeyleri, antioksidan sistemin işlerliğini tespitite doku SOD ve GSH-Px enzim düzeyleri, histopatolojik olarak, inflamasyon ve ödemin tespitinde rutin hematoksilen-eozin boyaması kullanıldı. Ayrıca oksijen konsantrasyonu arttığında azalan HIF1 aktivitesine, antiinflamatuvar etkilerinin olduğu gösterilen HO-1 aktivitesine, her türlü akut olayda salınan iNOS aktiviteyi de çalışmamızda tesbit edildi. Sonuç olarak, HBO ve ozon gruplarında LPO, iNOS düzeylerinde istatistiksel olarak anlamlı azalma tesbit ettik. Bu sonuçlarla uyumlu olarak; histopatolojik incelemede de kontrol grubuna kıyasla HBO ve Ozon gruplarında inflamasyonda anlamlı bir azalma ve her üç grupta ödemde anlamlı düşme mevcuttu. YDT'lerinde, HBO ve Ozon tedavisinin çalışmamızdaki biyokimyasal ve histopatolojik bulgulara göre faydalı etkilerinin olduğu değerlendirilmektedir. Konuyla ilgili klinik çalışmaların yapılması etkilerinin daha iyi irdelenmesi adına faydalı olacağı söylenebilir.

**Anahtar sözcükler:** Deneysel; hiperbarik oksijen; ozon; yumuşak doku travması.